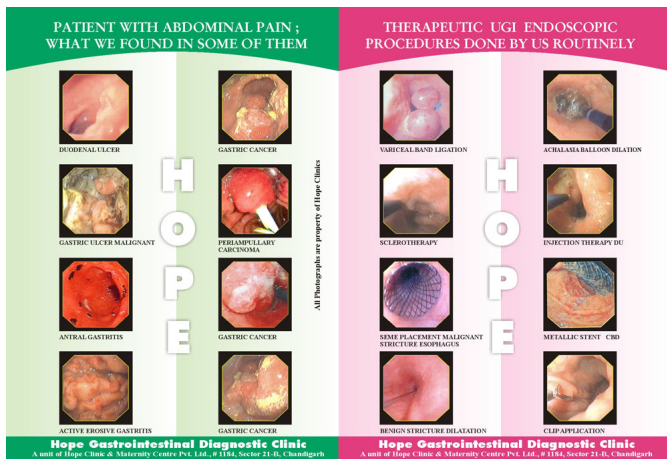

















Open access Upper Gastrointestinal Endoscopy (UGIE) was introduced by us in 1991 in this region. Fear of endoscopy was widely prevalent then and was present even among physicians. We introduced the concept that a doctor at his clinic can decide his patient requires UGIE refer the patient to us and like a ultrasound or X ray the patient can as easily get UGIE done and go back to his doctor immediately for further treatment with his report. We first introduced photographic documentation of endoscopic procedures in 1994-1995. Now with us UGIE takes 2-7 minutes to perform, and patient can leave with report within 30 minutes of his coming to our centre. Though we have facility for cardiac monitoring, SpO2 monitoring and boyles machine with piped oxygen supply in our endoscopy suite all this is rarely used specially when we perform UGIE for children under general anesthesia. Minimum age we have ever performed UGIE on is 9 mths and maximum is 104 yrs. We have multiple video endoscopes and have performed more than 50000 UGIEs todate. Our stress is on patient comfort, patient safety, and quality reporting. We perform all therapeutic Upper Gastrointestinal Endoscopic procedures including dilatations, endoprosthesis placement, polypectomies, percutaneous endoscopic gastrostomy, variceal band ligations, sclerotherapy, glue injection in fundal varices, clip application and other endoscopic treatments for bleeding duodenal / gastric ulcer. We are specially known for variety of foreign bodies that we have removed over the years from the UGI tract. Diagnostic UGIE carries no fear of any complications with us. We have had our share of complications when performing therapeutic endoscopic procedures though rarely so. Since we also have our inhouse operation theater and admission facility we have been able to successfully manage even problem cases.

| INTERESTING FOREIGN BODIES REMOVED BY US OVER THE YEARS ENDOSCOPICALLY | | WHY SOME OF OUR PATIENTS HAD DYSPHAGIA | |
|--|---|--|---|
|  TOOTH BRUSH |  COIN |  CARCINOMA ESOPHAGUS |  CARCINOMA LARYNX |
|  NEEDLE |  BULB |  REFLUX ESOPHAGITIS |  ACHALASIA CARDIA |
|  NAIL |  NAIL CUTTER |  PILL INDUCED ESOPHAGEAL ULCER |  BENIGN STRICTURE ESOPHAGUS |
|  DENTURE |  TONGUE CLEANER |  ESOPHAGEAL CANDIDIASIS |  ESOPHAGEAL WEB |

HOPE

All Dysphagias are property of Hope Clinic

Hope Gastrointestinal Diagnostic Clinic
A unit of Hope Clinic & Maternity Centre Pvt. Ltd., # 1154, Sector 21-B, Chandigarh

Hope Gastrointestinal Diagnostic Clinic
A unit of Hope Clinic & Maternity Centre Pvt. Ltd., # 1154, Sector 21-B, Chandigarh